

Efficacy of combination LED light therapy in rosacea management: a case series review



Dr Ian STRAWFORD¹, MRCGP MBCAM Cosmetic Doctor,
Lee Anne EVANS², Melissa WILLIAMS²

Presented at the IMCAS World Congress 2025,
30 January – 1 February 2025; Paris, France

1. Skin Excellence Clinics, Plymouth, United Kingdom;
2. Dermalux, Aesthetic Technology Ltd, Warrington, United Kingdom

Copies of this poster obtained through QR, AR and/or text key codes are for personal use only and may not be reproduced without written permission of the authors.

Introduction

- Light-emitting diode (LED) light therapy has demonstrated promising results in the treatment of inflammatory skin conditions, such as acne and psoriasis, by reducing inflammation and promoting skin healing.¹⁻³ While initial findings are encouraging for these conditions, evidence for the efficacy of LED light therapy in rosacea remains extremely limited^{3,4}
- This case series evaluates the therapeutic outcomes of using the Tri-Wave MD[®] (Dermalux) LED light therapy device in four patients with rosacea, exploring the efficacy of blue, red and near-infrared (NIR) LED light combination phototherapy

Results

- All patients experienced improvements in overall skin quality, decreased inflammation and diminished pigmentation
- No adverse reactions, such as photosensitivity, were reported by any patient
- All four patients were satisfied with the outcomes, self-reporting enhanced self-confidence and overall mood

Materials / Methods

- Four female patients (aged 36–59 years) with rosacea and Fitzpatrick skin types II–III, some with other inflammatory co-existing conditions such as acne or psoriasis, were treated with the Tri-Wave MD[®] device (Dermalux). All patients provided informed consent to participate in the study and for their images to be used for publication purposes
- Treatment was weekly for 20 mins/week over 6 weeks using a combination of blue, red and NIR light. Each patient received a personalised treatment plan with different wavelengths and energy (see images and tables below)



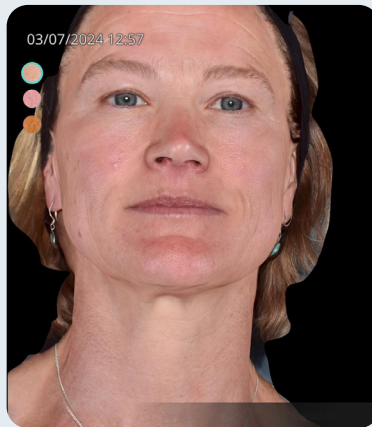
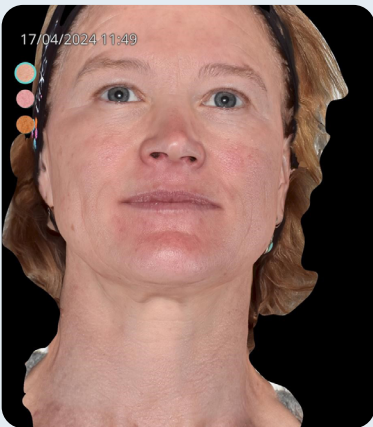
Conclusions

- To the best of our knowledge, this is one of the few documented case series of patients with rosacea successfully treated with combination LED light therapy
- This case series indicates that combination LED phototherapy is effective in treating inflammatory skin conditions, with the added secondary benefit of improving patients' self-confidence and mood; however, more evidence is required to establish the optimum treatment protocol for rosacea
- Although no adverse reactions were observed, further studies are necessary to determine any potential short- and long-term treatment-related adverse effects

Patient 1

Before

After



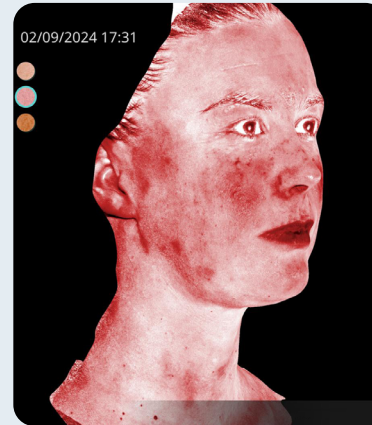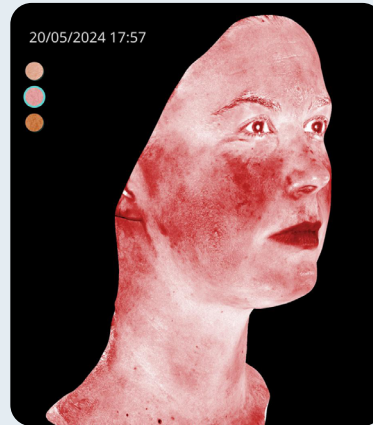

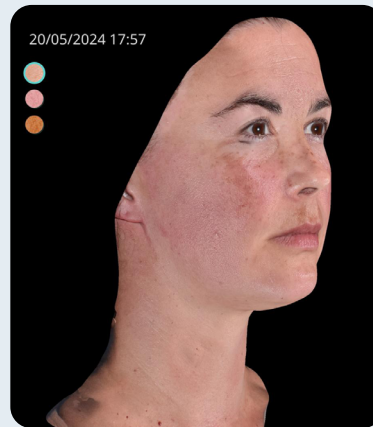Baseline characteristics and treatment protocol				
Age (yrs)	Sex	Fitzpatrick skin phototype	Presentation	Occupation/ relevant history
51	F	III	Intermittent adult acne, inflammation and rosacea	Accountant, concomitant topical acne medications produced moderate benefits
Blue light (J)	Red light (J)	NIR light (J)	Sessions (n)	Length of sessions (mins)
30	69	38	6	20

In patient 1, reduced inflammation was observed together with control of acne outbreaks. Following the completion of treatment, patient 1 continues to receive LED light therapy (using the Dermalux monthly maintenance protocol*) in combination with topical skin medications to control acne.

Patient 2

Before

After



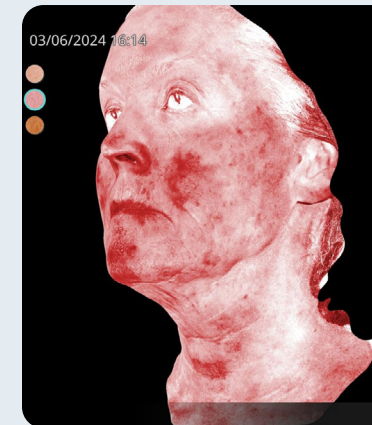
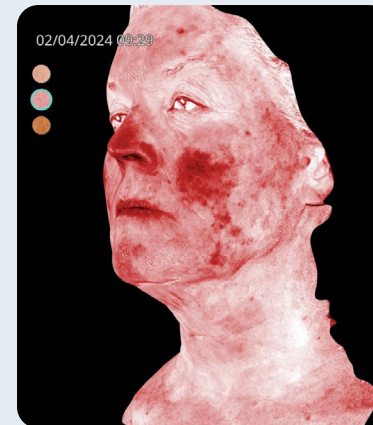
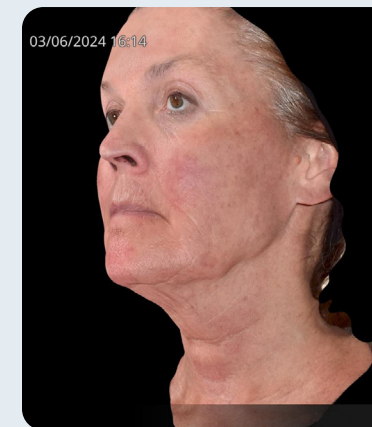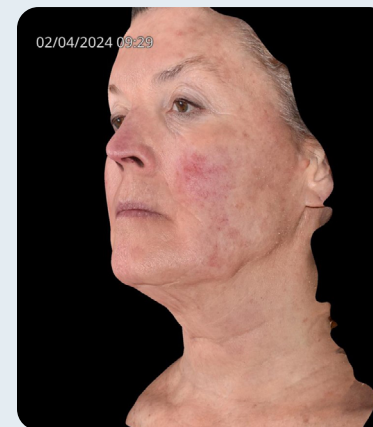Baseline characteristics and treatment protocol				
Age (yrs)	Sex	Fitzpatrick skin phototype	Presentation	Occupation/ relevant history
36	F	III	Hyperpigmentation and rosacea with inflammation	Gardener, uses sun protection
Blue light (J)	Red light (J)	NIR light (J)	Sessions (n)	Length of sessions (mins)
-	69	66	6	20

In patient 2, a significant lifting effect of 2–4 mm was observed in addition to improvement in skin quality, inflammation, pigmentation.

Patient 4

Before

After



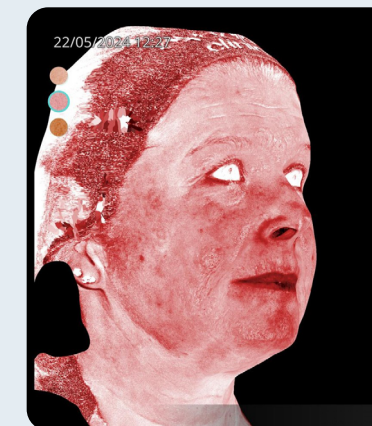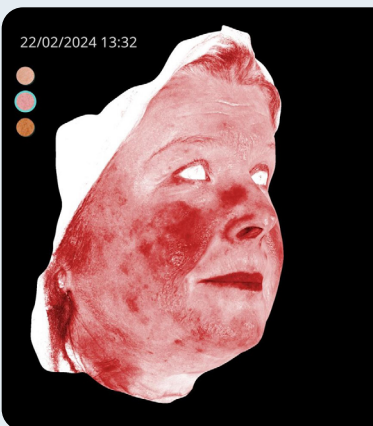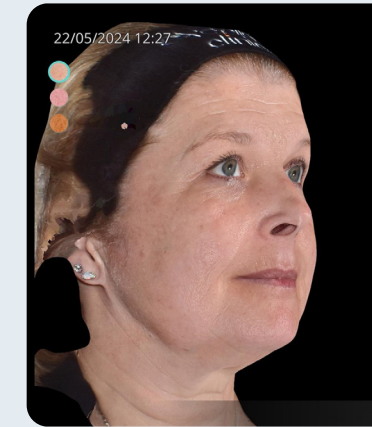
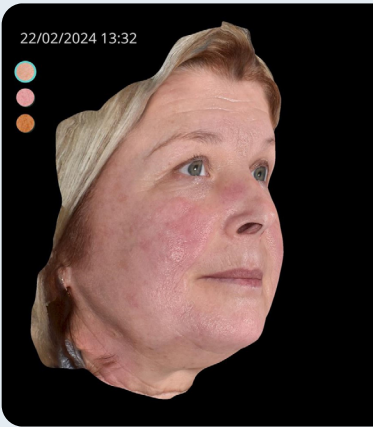Baseline characteristics and treatment protocol				
Age (yrs)	Sex	Fitzpatrick skin phototype	Presentation	Occupation/ relevant history
59	F	II	Hyperpigmentation, sun damage, rosacea	Retiree, history of high UV exposure from living in the Far East
Blue light (J)	Red light (J)	NIR light (J)	Sessions (n)	Length of sessions (mins)
-	34	19	8	20*

In patient 4, who presented with significant hyperpigmentation and a history of extensive photodamage, both significant reduced inflammation and pigmentation were observed.

Patient 3

Before

After



Baseline characteristics and treatment protocol				
Age (yrs)	Sex	Fitzpatrick skin phototype	Presentation	Occupation/ relevant history
49	F	II	Rosacea	Office worker, avoids outdoors to prevent rosacea exacerbation
Blue light (J)	Red light (J)	NIR light (J)	Sessions (n)	Length of sessions (mins)
-	34	19	5	10
-	126	66	1	20

Patient 3 experienced significant improvements in skin quality, reduction in inflammation and pigmentation, along with the greatest improvement in quality of life among all patients. Initially, she reported being unable to conceal her condition with makeup and was restricted from spending much time outdoors, even with SPF protection. This limitation severely affected her lifestyle, preventing her from enjoying outdoor activities and causing considerable psychological distress. Following LED light treatment, she is now able to participate in outdoor activities during the summer, while using sun protection and maintenance monthly LED light therapy.¹

Disclaimers

- This work is presented thanks to the support of Dermalux, Aesthetic Technology Ltd. Medical writing support was provided by NexGen Healthcare Communications.
- Dr Ian Strawford is a paid consultant to Dermalux Aesthetic Technology Ltd. As part of this consultancy, he is provided with Dermalux devices and compensated for testing these and providing expert clinical advice. The opinions expressed in this publication are solely those of the author and are not influenced by his consultancy relationship with Dermalux Aesthetic Technology Ltd.

Abbreviations

AR, augmented reality; F, female; IMCAS, International Master Course on Aging Science; J, joule; LED, light-emitting diode; NIR, near-infrared; QR, quick response; SPF, sun protection factor; UV, ultraviolet.

Footnote

*Red 633 nm only used in the final 10 mins of the full treatment time.

¹The maintenance Dermalux protocol involves monthly sessions, which comprise combinations of blue, red and NIR light for 10–20 mins monthly dependent on the patient's ongoing medical condition.

References

- Ablon G. J Clin Aesthet Dermatol. 2018;11:21–7.
- Edge D, et al. J Clin Aesthet Dermatol. 2019;12:E61–8.
- Sorbellini E, et al. J Med Case Rep. 2020;14:22.
- Sannino A, et al. Clin Case Rep. 2018;6:2385–390.